

Pediatric Orbital Cellulitis and Abscess



Mt. Nasu

Keiichi Ichimura,
MD, PhD

Department of Otolaryngology-H & N Surgery
Jichi Medical University School of Medicine
Shimotsuke, Japan

Faculty Disclosure

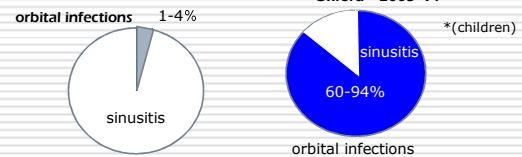
I advise that the following presentation will NOT include discussion on any commercial products or service and that there are NO financial interests or relationships with any of the Commercial Supporters of The Asia-Oceania Otolaryngology Congress.

Today's Summary on Orbital Complications of Acute Sinusitis

- The classifications of orbital complications presented are not related with progression of disease stage
- CT or MRI is necessary for differentiating orbital cellulitis and abscess
- Therapeutic strategy is antibiotic treatment alone and, in cases of abscess, followed by surgical drainage
- Subperiosteal abscess in a younger population is a candidate of medical management

Incidence of Orbital Complications

	N		
Iwazskiewicz	1936	732	3%
Schlittler		2225	1
Marx	1949	100	4
Brockmuhl	1963	1609	3.9
Birch	1930		60%
Porter	1932	73 (82)*	
Davis	1937		72
Wellner	1941		70
Moloney	1987		66
Oxford	2005		91

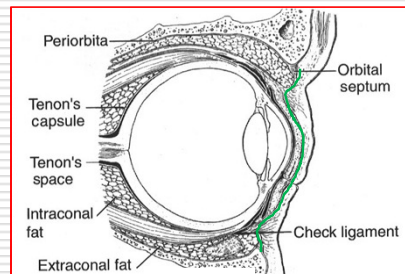


Classification of Orbital Complications

group	Hubert 1937	Smith & Spencer 1948	Chandler et al. 1970	Moloney et al. 1987
1	eyelid inflammatory edema	inflammatory edema of the eyelid	inflammatory edema	preseptal cellulitis
2	orbit SPA	SPA	OC	SPA
3	diffuse OC	OA	SPA	OC
4	OA	OC	OA	OA
5	CST	CST	CST	CST

SPA; subperiosteal abscess, OC; orbital cellulitis
OA: orbital abscess, CST: cavernous sinus thrombosis

Orbit and Orbital Septum

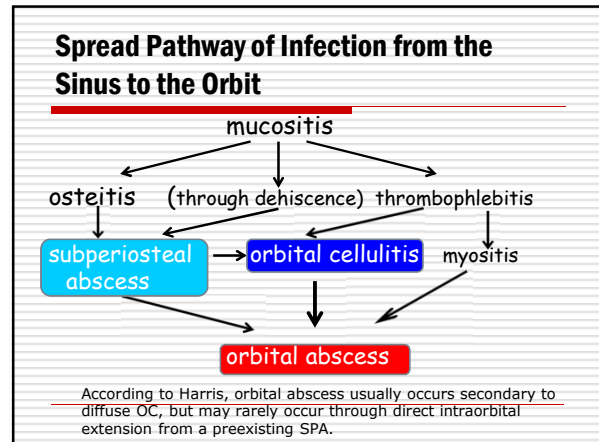


Paediatric pre- and post-septal peri-orbital infections are different diseases

A retrospective review of 262 cases.
 Botting AM, McIntosh D, Mahadevan M
Int J Pediatr Otorhinolaryngol 2008;72:377-383.

227 preseptal and 35 postseptal cases

differences:
 age, medical co-morbidities, history of trauma, acute sinusitis, fever, diplopia, ophthalmoplegia, proptosis, surgical necessity



D.D. of SPA and OC

- ❑ SPA is characterized by global dislocation, but cannot be differentiated from OC clinically, especially in pediatric cases
- ❑ Image diagnosis using CT or MRI is mandatory
- ❑ Incidence of unidentified SPA in CT : 16%

OC seems to be more dangerous than SPA in progressing to orbital abscess

Indications of Surgery

Cellulitis → medical (if unresponsive) → surgical
 Abscess → surgical

- ❑ A decrease in vision occurs.
- ❑ An afferent pupillary defect develops.
- ❑ Proptosis progresses despite appropriate antibiotic therapy.
- ❑ The size of the abscess does not reduce on CT scan within 48-72 hours after appropriate antibiotics have been administered. (Harrington JN, 2010)

How to treat Pediatric SPA?

- ❑ Controversy exists about the optimal management of a pediatric SPA
- ❑ A shift toward using only medical therapy in the treatment of pediatric SPA began in the 1980s. Harris is to be credited with making this paradigm shift.
- ❑ Before this time, virtually all patients were treated with incision and drainage of the abscess.

Age as a Factor of Therapeutic Choice

- ❑ Aerobes are identified independently in children of 9 years and younger and likely to respond to antibacterials. (Harris,1994)
- ❑ In older children both aerobes and anaerobes identified together and needs surgical drainage. (Brook & Frazier,1996)
- ❑ Children under 6 years usually suffer from medial SPA and respond well to antibiotics. (Greenberg & Pollard,1998)
- ❑ SPA located other than medial wall of the orbit are likely to present in older children. Superior wall SPA is likely to develop into an intracranial infection.

Criteria for Medical Management of Medial SPA

1. normal vision, pupil, and retina
2. no ophthalmoplegia in one or more directions of gaze
3. intraocular pressure <20mmHg
4. proptosis of 5mm or less
5. width of 4mm or less on CT

(Oxford and McClay,2006)

They insisted older children ages under 9 were successfully treated medically

Current Japanese Situation of Treatment for Orbital Infections

- Intravenous antibiotic therapy as an inpatient basis is a rule
- No treatment guidelines has been available so far
- Retrospective study of orbital complications experienced in our hospital and Japanese literature survey were performed

JMUH Study

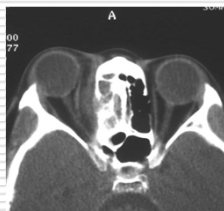- The charts of 18 pediatric cases of acute sinusitis complicated with orbital complications in JMUH and affiliated hospitals from 1999 to 2009 were investigated retrospectively.
- preseptal cellulitis 9
- OC 5
- SPA 4



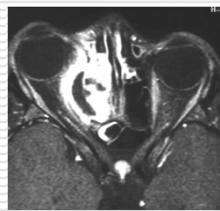
Results

- It was difficult in distinguishing cellulitis and abscess clinically.
- As MRI is superior to CT in the resolution of soft tissue disease, it surely seemed superior in distinguishing OC and SPA.
- All patients with OC and SPA were treated with intravenous antibiotics.
 - All patients with OC did well with medical management.
 - Medial wall SPA in 3 cases aged 7, 7, and 8, respectively, were well controlled with IV antibiotic treatment.

Surgical treatment was required only in one SPA patient aged 12 years.



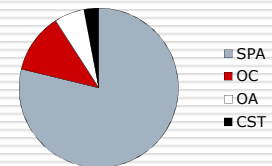
plain CT axial

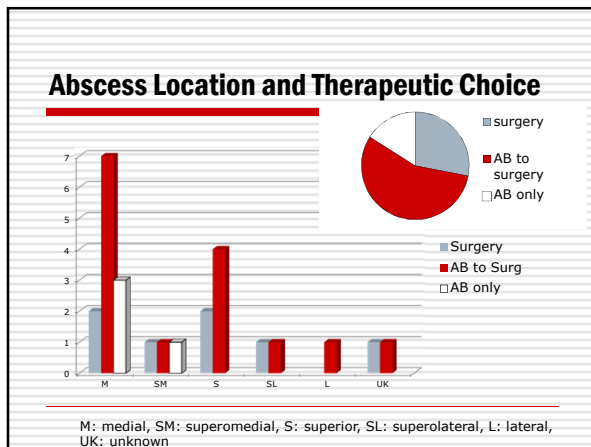
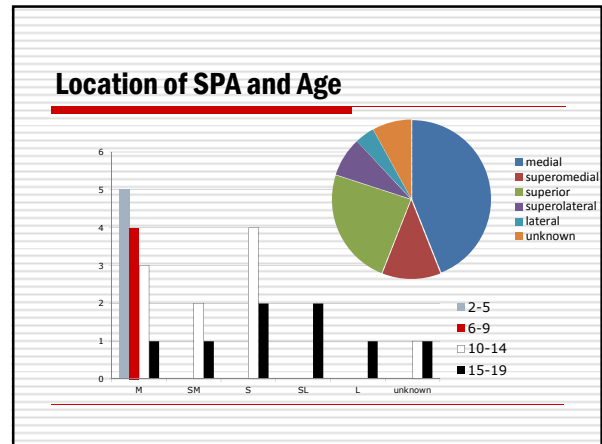
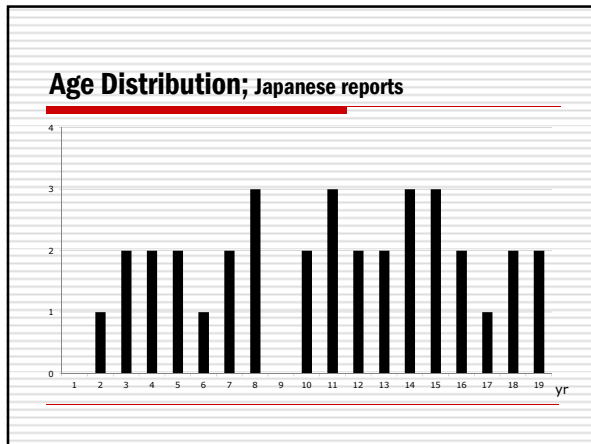


enhanced T1 weighted MRI

Japanese Literature Study

- Case reports of orbital complications of acute sinusitis published in Japanese literature from 1993 to 2010 were collected.
- Classification





Why Japanese Pediatric SPA Cases underwent Surgery often?

- Surgeons are likely to report surgical cases. On the other hand, successfully treated cases with antibiotics are unlikely reported.
- All abscesses located other than medial or superomedial wall required surgical drainage.
- Medial SPA may still be a candidate for medical therapy.

Conclusions

- If MRI is quickly available, this is the choice.
- Medical therapy is enough if the abscesses are situated in the medial orbital wall in children up to eight years of age.
- Surgical indications of acute orbit
 - Any conditions unresponsive to antibiotic therapy in 48 hours
 - All abscesses except for SPA at the medial orbital wall in children less than 9 years

IRS & ISIAN 2011 will be held in Tokyo, Japan on April 6-9.

Let's join us and have fantastic days then.